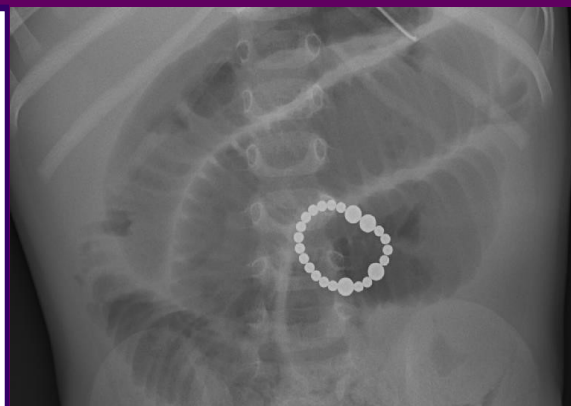

Ingestion of super strong magnets in children

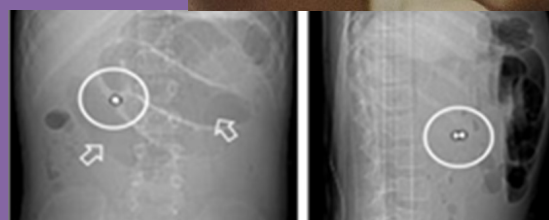



An 18 month old child presented twice to the ED with vomiting and poor appetite. Operative findings: Over 20 adhered "super-strong" magnetic balls causing fistulation & volvulus of jejunal and ileal loops.

Intestinal injury can occur within 8-24 hours following ingestion, but may not manifest itself for weeks after ingestion

A **symptomatic** patient who has ingested an super-strong magnet is a **TIME CRITICAL EMERGENCY** and should prompt surgical review

- Super-strong magnets are found in desk toys, toys & fake piercings
- Consider the possibility of super-strong magnet ingestion in patients with unexplained respiratory and abdominal symptoms
- **DO NOT** use metal detectors, imaging is required
- If a magnet is seen on CXR or AXR, get a **lateral film** to assess the number of magnets and their position
- Passage of magnets to the stomach **cannot** be used as a criterion that the child is free from a potentially catastrophic underlying Injury
- The progression of the extra strong magnet(s) through the GI tract is crucial to whether surgical intervention is required
- Asymptomatic patients with magnet ingestion require follow-up imaging 6-12 hours after initial X Ray & robust safety netting



Available via license: [CC BY-NC-ND 4.0](https://creativecommons.org/licenses/by-nc-nd/4.0/)

For more information and management flowchart please see:

[RCEM Best Practice guidance Ingestion of super-strong magnets in children](#) / [NHSE&I National Patient Safety Alert](#)

For Safety Alerts and RCEM issued Safety Flashes see:

www.rcem.ac.uk/SafetyAlerts